

# Development and Validation of Diagnostic Criteria for Acute Cholangitis: A Multidisciplinary Approach

**Taro Yamada, Hiroshi Nakamura, Kenji Kondo**

*Department of Surgery, Osaka University Graduate School of Medicine, 2-2 Yamadaoka, Suita, Osaka 565-0871, Japan; Department of Gastroenterology, National Center for Global Health and Medicine, 1-21-1 Toyama, Shinjuku-ku, Tokyo 162-8655, Japan; Division of Hepatobiliary and Pancreatic Surgery, University of California, San Francisco, 513 Parnassus Avenue, San Francisco, CA 94143-0798, USA*

**Citation:** Taro Yamada, Hiroshi Nakamura, Kenji Kondo (2026). Development and Validation of Diagnostic Criteria for Acute Cholangitis: A Multidisciplinary Approach. *Psychiatry*, 18(2), 52-66. <https://doi.org/10.5281/zenodo.19096925>

**Abstract** Although the diagnostic and severity grading criteria on the 2013 Tokyo Guidelines (TG13) are used worldwide as the primary standard for management of acute cholangitis (AC), they need to be validated through implementation and assessment in actual clinical practice. Here, we conduct a systematic review of the literature to validate the TG13 diagnostic and severity grading criteria for AC and propose TG18 criteria. While there is little evidence evaluating the TG13 criteria, they were validated through a large-scale case series study in Japan and Taiwan. Analyzing big data from this study confirmed that the diagnostic rate of AC based on the TG13 diagnostic criteria was higher than that based on the TG07 criteria, and that 30-day mortality in patients with a higher severity based on the TG13 severity grading criteria was significantly higher. Furthermore, a comparison of patients treated with early or urgent biliary drainage versus patients not treated this way showed no difference in 30-day mortality among patients with Grade I or Grade III AC, but significantly lower 30-day mortality in patients with Grade II AC who were treated with early or urgent biliary drainage. This suggests that the TG13 severity grading criteria can be used to identify Grade II patients whose prognoses may be improved through biliary drainage. The TG13 severity grading criteria may therefore be useful as an indicator for biliary drainage as well as a predictive factor when assessing the patient's prognosis. The TG13 diagnostic and severity grading criteria for AC can provide results quickly, are minimally invasive for the patients, and are inexpensive. We recommend that the TG13 criteria be

adopted in the TG18 guidelines and used as standard practice in the clinical setting. Free full articles and mobile app of TG18 are available at: [http://www.jshbps.jp/modules/en/index.php?content\\_id=47](http://www.jshbps.jp/modules/en/index.php?content_id=47). Related clinical questions and references are also included.

**Keywords** Acute cholangitis Diagnostic criteria Diagnostic imaging Guidelines Severity grading

## Introduction

Acute cholangitis (AC) occurs when biliary stenosis, due to various benign causes (often bile duct stones) or the presence of a tumor, results in cholestasis and biliary infection. This biliary stenosis or blockage elevates pressure within the biliary system and flushes the microorganisms or endotoxins from the infected bile into systemic circulation, inducing a systemic inflammatory response [1, 2]. Mortality risk is high if the condition is not treated with antibiotic therapy and biliary pressure is not immediately reduced using appropriate methods. We, therefore, need to be able to reliably diagnose and assess the severity of cholangitis to determine whether the patient's life is in danger.

However, very little evidence related to AC has been collected over the years, and the evidence that does exist is extremely old. No globally accepted diagnostic criteria for AC have existed. Although AC has long been diagnosed on the basis of Charcot's triad, as discussed in greater detail below, this method is problematic because of its low sensitivity (around 26%). The lack of evidence in this field has prompted specialists to establish a consensus. Thus, the International Consensus Meeting for the Management of Acute Cholecystitis, Cholangitis was held on 1–2 April 2006 in Tokyo, Japan. Based on the outcomes from this meeting and a systematic review of the literature, the Tokyo Guidelines for the management of AC and cholecystitis (TG07) were published in 2007 and the first ever diagnostic and severity grading criteria for AC were presented [2]. However, validation of the TG07 diagnostic criteria in actual clinical practice revealed that these guidelines were not sufficiently sensitive to identify potentially life-threatening cases [3, 4]. Moreover, the TG07 severity grading criteria were found to be of limited use due to the ambiguous definition of moderate cholangitis as "not responding to initial treatment" and the lack of methodologies allowing clinicians to carry out rapid assessment at the time of diagnosis [3–6]. In 2013, therefore, the criteria for diagnosis and severity grading of AC were amended and reintroduced as the updated TG13 guidelines [5], based on a systematic review of the literature, international consensus meetings, and multicenter study.

Today, it is recommended to manage AC by referring to the globally accepted diagnostic criteria and severity grading criteria as defined in the TG13 guidelines. However, the criteria for diagnosis and severity grading defined in these guidelines also need to be re-examined and amended after implementation and assessment in the clinical setting [7]. TG13 also needs to be validated through application in clinical practice. Here, we validate the criteria for diagnosis and severity grading of AC in the TG13 guidelines based on a systematic review of the literature and, in particular, a large-scale Japanese/Taiwanese joint case series study and propose diagnostic and severity grading criteria for the TG18 guidelines.

Diagnostic criteria for acute cholangitis

Q1. What is the role of Charcot’s triad in the diagnostic criteria for acute cholangitis? [Background question]

Charcot’s triad shows very high specificity. The presence of Charcot’s triad strongly suggests the presence of acute cholangitis. However, due to the low sensitivity, it is not applicable in using as diagnosis criteria for acute cholangitis. (Level D)

Acute cholangitis has long been diagnosed on the basis of Charcot’s triad, which relies on clinical signs [8]. Although Charcot’s triad provides highly specific diagnostic criteria [9], studies have reported its sensitivity to be on the order of 50 to 70% [9–16]. More recent multicenter case series studies showed Charcot’s triad diagnosis rates to be much lower (26.4% [4] and 21.2% [17]). Thus, the ability of this method to diagnose AC is severely limited.

To compensate for the low sensitivity of Charcot’s triad, the TG07 diagnostic criteria were based on Charcot’s triad with the addition of blood test and imaging findings; however, this still did not provide sufficient sensitivity. In the updated TG13 guidelines, the Tokyo Guidelines Revision Committee conducted joint research at multiple sites. Initially, when the TG07 items were reclassified as three main clinical manifestations based on Charcot’s triad, the method had exhibited good sensitivity (95.1%) but poor specificity (66.3%) due to the high rate (38.8%) of false positives for acute cholecystitis. Excluding abdominal pain, one of the Charcot’s triad, gave 91.8% sensitivity and 77.7% specificity, with a 5.9% false positive rate for acute cholecystitis; so, this was used as the updated TG13 diagnostic criteria [4, 5].

Q2. Are the TG13 diagnostic criteria for acute cholangitis useful for clinical practice and appropriate as the TG18 criteria? [Foreground question]

The TG13 diagnostic criteria are recommended to be used as the TG18 criteria because more patients with possible acute cholangitis can be diagnosed by using these criteria. (Recommendation 1, level D)

The entire literature on TG13 diagnostic criteria for AC consisted of two case series studies [17, 18], indicating the paucity of studies in this area. Recently a largescale multicenter case series study to validate the TG13 diagnostic criteria for AC was conducted at sites in Japan and Taiwan [17]. This study enrolled patients who were clinically diagnosed with AC and admitted for treatment over a 2-year period between 2011 and 2013, prior to the publication of the TG13 guidelines. Retrospective

Table 1 Comparison of diagnostic rates of TG13 and TG07 [17]

Diagnostic status	No. of patients		P-value
	TG13	TG07	
Definite	4,430 (73.1%)	3,977 (65.6%)	
Suspected	1,024 (16.9%)	838 (13.8%)	
Cholangitis (definite or suspected diagnosis)	5,454 (90.0%)	4,815 (79.4%)	<0.0001
Non-cholangitis	609 (10.0%)	1,248 (20.6%)	

Cited from Kiriya et al. [17]

application of the TG13 diagnostic criteria to the patients suspected of AC on a clinical basis yielded definite and suspected diagnoses in 5,454 of 6,063 patients for a diagnosis rate of 90.0%. Application of TG07 diagnostic criteria resulted in definite and suspected diagnoses in 4,815 patients for a diagnosis rate of 79.4%, confirming that TG13 provides improved diagnostic capabilities for AC (Table 1). Systemic inflammation was not observed in 511 of the 609 patients (83.9%) who did not receive a definite or suspected diagnosis based on the TG13 diagnostic criteria. Moreover, of the 2,523 Grade I patients, the diagnosis rate based on the TG13 diagnostic criteria was only 83.6%; analysis by causative factor showed a high diagnosis rate in cases where the cholangitis had a clear cause (bile duct stones, malignant tumors, and stent occlusion) but a low diagnosis rate for other types of cholangitis including cases where the cause was unknown. There are still limitations that must be

overcome, including the low diagnosis rates in patients with mild disease, patients where findings of a systemic inflammatory response are lacking, or patients where imaging is difficult to obtain and the cause cannot be readily identified. That said, the diagnosis rates based on TG13 are better than those based on TG07. Limitations of this study include the fact that the decision processes used at each facility to diagnose and treat AC of the enrolled patient may have differed and the fact that specificity was not assessed. Note that one report showed roughly equivalent diagnosis rates with TG13 and TG07 [18]; however, this study only investigated cases with a definite diagnosis of AC with confirmed purulent bile, which is a subset of AC cases targeted by the diagnostic and therapeutic guidelines. This may explain the high diagnosis rates in that report resulting from the TG07 diagnostic criteria based on Charcot's triad.

The systematic review of the literature performed for the TG18 revision revealed that there is little evidence validating the diagnostic capabilities of the TG13 diagnostic criteria for AC and that no studies have evaluated specificity. However, in terms of diagnostic criteria, sensitivity is more important than specificity for this disease, which can be life-threatening if not diagnosed rapidly and treated appropriately. Large-scale case series research showed that the TG13 diagnostic criteria for AC are associated with high diagnosis rates of around 90% for cases actually treated as AC. Moreover, when the TG13 diagnostic criteria are used, clinicians can make a diagnosis based on clinical signs and symptoms, routine blood tests, and diagnostic imaging, all of which can be performed and provide results quickly, are minimally invasive for the patients, and are inexpensive.

We therefore recommend that the TG13 diagnostic criteria for AC be adopted as TG18 diagnostic criteria and used as standard practice in the clinical setting. Table 2 shows the TG18/TG13 diagnostic criteria for AC.

Table 2 TG18/TG13 diagnostic criteria for acute cholangitis [4]

- 
- A. Systemic inflammation
    - A-1. Fever and/or shaking chills
    - A-2. Laboratory data: evidence of inflammatory response
  - B. Cholestasis
    - B-1. Jaundice
    - B-2. Laboratory data: abnormal liver function tests
  - C. Imaging
    - C-1. Biliary dilatation
    - C-2. Evidence of the etiology on imaging (stricture, stone, stent etc.)

Suspected diagnosis: one item in A + one item in either B or C  
 Definite diagnosis: one item in A, one item in B and one item in C

---

Note:

A-2: Abnormal white blood cell counts, increase of serum C-reactive protein levels, and other changes indicating inflammation

B-2: Increased serum ALP, r-GTP (GGT), AST, and ALT levels

Other factors which are helpful in diagnosis of acute cholangitis include abdominal pain (right upper quadrant or upper abdominal) and a history of biliary disease such as gallstones, previous biliary procedures, and placement of a biliary stent. In acute hepatitis, marked systematic inflammatory response is observed infrequently.

Virological and serological tests are required when differential diagnosis is difficult.

Thresholds:

---

			BT >38°C
A-1	Fever		
A-2	Evidence of inflammatory response	WBC count (91,000/IL) CRP (mg/dL)	<4 or >10 ≥1
B-1	Jaundice		T-Bil ≥2 (mg/dL)
B-2	Abnormal liver function tests	ALP (IU) cGTP (IU)  AST (IU)  ALT (IU)	>1.5 9 STD <sup>a</sup> >1.5 9 STD <sup>a</sup>  >1.5 9 STD <sup>a</sup>  >1.5 9 STD <sup>a</sup>

---

Cited from Kiriya et al. [4]

ALP alkaline phosphatase, ALT alanine aminotransferase, AST aspartate aminotransferase, CRP C-reactive protein, r-GTP (GGT) r-glutamyltransferase, WBC white blood cell

<sup>a</sup> STD: upper limit of normal value

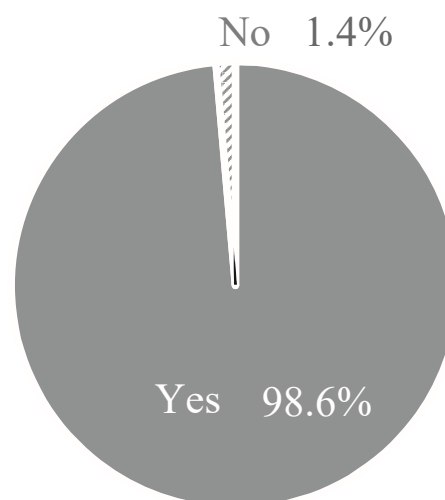


Fig. 1 Response to the question: "Do you agree with the suggestion that TG13 diagnostic criteria for acute cholangitis would be adopted as the TG13/TG18 criteria without revising setting?"

At the Updating the Tokyo Guidelines Public Hearing, the majority of attendees (98.6%) agreed that the TG13

diagnostic criteria on AC should be adopted as the TG18/TG13 diagnostic criteria on AC (Fig. 1).

According to the TG18/TG13 diagnostic criteria, a diagnosis of AC can be made if the patient presents with the three pathologies of systemic inflammation (must be present), cholestasis, and bile duct lesions (from imaging findings).

#### Systemic inflammation

In the TG18/TG13 diagnostic criteria for AC, a diagnosis of AC requires findings of systemic inflammation, based on fever or an elevated inflammatory response (elevated leukocytes, high C-reactive protein). Fever is defined as a temperature of 38°C or above, but mild cases can exhibit only minor increases in body temperature. With such cases, diagnosis can be made with additional blood test findings. However, the potential inability to diagnose mild cases has been cited as one of the limitations of the TG18/TG13 diagnostic criteria [17].

#### Cholestasis

Cholestasis is a key clinical feature of AC. Jaundice, one of the symptoms in Charcot's triad, is only observed in 60 to 70% of patients with AC [9–16]. With the TG18/ TG13 diagnostic criteria for AC, a diagnosis of AC can still be made in the absence of jaundice, based on elevated alkaline phosphatase (ALP), gamma-glutamyltransferase (GTP), leucinaminopeptidase and transaminases (aspartate aminotransferase (AST) and alanine aminotransferase (ALT)) in the blood test results.

#### Imaging findings

Remarkable advances have been made in the equipment and methods used for diagnostic imaging [19–21]. However, even though new technologies and knowledge are steadily accumulating, we are still unable to directly diagnose AC based on imaging findings. Even in the TG13 guidelines, diagnostic imaging is considered a method to directly identify biliary stenosis/blockage that can cause AC or to describe cholangiectasis that can be used as an indirect finding in support of a diagnosis [5]. Imaging modalities capable of yielding such findings include abdominal ultrasound, computed tomography (CT), and magnetic resonance imaging (MRI)/magnetic resonance cholangiopancreatography (MRCP) [5, 22], whereas simple X-rays are not suited to diagnoses. Endoscopic retrograde

cholangiopancreatography is performed for the purposes of treatment (drainage), but is not suitable as first choice for diagnostic purposes.

Q3. What are useful imaging methods for acute cholangitis?

Should ultrasound or CT be performed to identify the cause of acute cholangitis and demonstrate biliary stenosis? (Recommendation 1, level D)

The literature contains no reports on diagnosis of AC using abdominal ultrasound and only reports on diagnostic capabilities for biliary stenosis/blockage that can cause AC. Abdominal ultrasound can readily detect abnormal dilation of the bile duct and, at the same time, be used to identify the cause (Figs 2, 4a). Bile duct stones present as highly echoic nodular lesions that cast an acoustic shadow, whereas with malignant stenosis of the bile duct, the mass around the stenosed bile duct can be identified as a normal, low-echo region. According to a meta-analysis by Abboud et al., abdominal ultrasound has a sensitivity of 42% (95% CI: 28 to 56%) and a specificity of 96% (95% CI: 94 to 98%) for dilated common bile duct and a sensitivity of 38% (95% CI: 27 to 49%) and a specificity of 100% (95% CI: 99 to 100%) for all bile duct stones. These results show that abdominal ultrasound has high specificity but insufficient sensitivity [23]. Another report on patients with obstructive jaundice where abdominal ultrasound was used to determine the cause [24] showed diagnostic sensitivity and specificity of 100% and 89%,

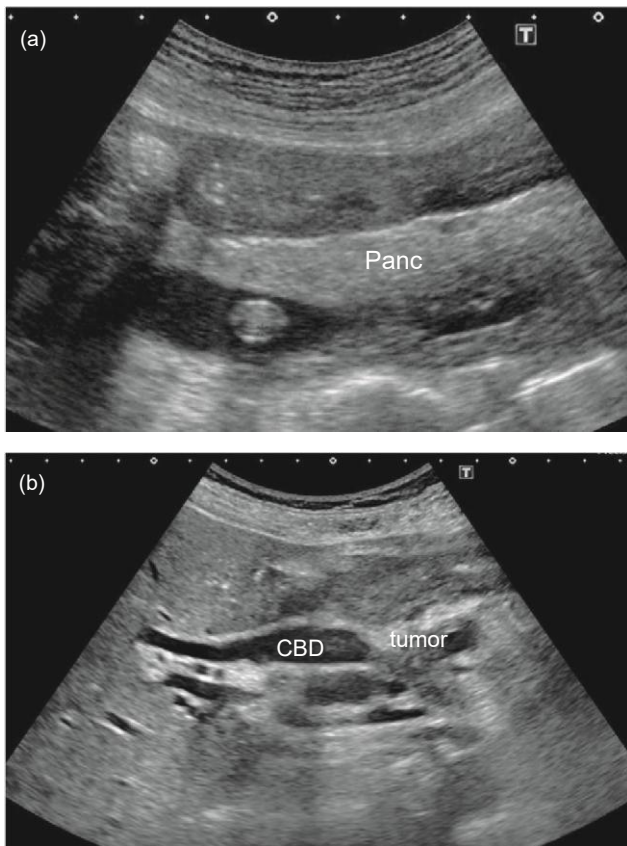


Fig. 2 Identification of the cause of acute cholangitis by abdominal ultrasound. (a) Stone in the common bile duct in a patient with acute cholangitis. The stone can be seen as hyperechoic nodule with slight acoustic shadow in the intrapancreatic common bile duct. (b) Cholangitis caused by cancer of the pancreatic head. The bile duct is clearly dilated and the duct is abruptly blocked by a tumor of the pancreatic head

respectively, for bile duct stones and 98.78% and 83.33%, respectively, for bile duct cancer. There are various disadvantages relating to the accuracy of abdominal ultrasound such as the greater likelihood of being affected by technician experience and clinical condition of the patient compared to CT scans [25], but abdominal ultrasound should be performed initially in patients with suspected AC given its minimal invasiveness, wide availability, convenience, and cost effectiveness.

Unlike abdominal ultrasound, CT imaging is not affected by intestinal gas and thus can be used to objectively identify high-attenuated nodules in the bile duct (Fig. 3a). However, because the CT value of bile duct stones depends on the amount of calcium phosphate or calcium carbonate in the stones [26], the detection sensitivity of CT is only 25 to 90% [27] (Fig. 4b). CT imaging can clearly identify bile duct dilatation and can contribute to much better diagnoses of the cause of biliary stenosis (e.g. biliary carcinoma, pancreatic cancer, or sclerosing cholangitis) (Fig. 5). CT imaging is also

useful for diagnosing local complications (e.g. liver abscess or portal vein thrombosis) [27–30] (Figs 6, 7).

MRCP is a non-invasive method that can delineate the bile duct and is a good option for identifying malignant disease or bile duct stones causing a biliary obstruction [31] (Figs 3f, 4d).

In the clinical setting, when a patient presents with acute abdominal pain, CT is often performed ahead of abdominal ultrasound as it can image wide areas and is therefore useful for excluding other diseases. Although MRI/MRCP are objective imaging methods with sufficient diagnostic capabilities, they are usually not the first-choice test method for reasons of availability and convenience.

Q5. Are MRI/MRCP tests recommended in acute cholangitis? [Foreground question]

MRI/MRCP are recommended, as they are useful when diagnosing the cause of acute cholangitis and evaluating inflammation. (Recommendation 2, level C)

Because of limited accessibility, MRI/MRCP are generally only used for imaging when a diagnosis proves difficult or uncertain with abdominal ultrasound or CT. MRI provides superior contrast resolution and allows the operator to image any cross-section; furthermore, MRCP can clearly delineate the bile duct without the use of a contrast agent. There is no question, therefore, that MRI/MRCP are useful modalities for biliary diseases [31] (Figs 3c-f, 4c, d). Calculi can be seen as obvious signal voids in the bile that present as a high signal on T2 weighted images (Figs 3d, e, 4c). Because T1 weighted images can depict calcium bilirubinate stones as high signal intensities, fatsuppressed T1 weighted imaging is a useful sequence to detect microcalculi [32] (Fig. 3c). Research comparing the diagnostic accuracy of MRI/MRCP, CT, and abdominal ultrasound in obstructive jaundice showed MRCP to have the best diagnostic capabilities, with benign and malignant disease being identified in 98% and 98% of cases, respectively, with MRI/MRCP, 82.86% and 91.43% of cases with CT, and 88% and 88% of cases with abdominal ultrasound [33]. Imaging findings with AC include increased signal around the bile duct on T2-weighted images and heterogeneous enhancement of the bile duct wall, abscesses, and portal vein thrombosis on contrast enhanced T1-weighted images, underlining the utility of this method in the diagnosis of AC and complications [34]. MRI/MRCP tests are therefore recommended when abdominal ultrasound or CT imaging do not provide a definite diagnosis.



Fig. 3 Example of non-incarcerated common bile duct stones. (a) Precontrast CT, (b) contrast-enhanced CT, (c) T1-weighted MRI, (d) T2weighted MRI single shot fast spin echo (SSFSE), (e) coronal T2-weighted MRI SSFSE, and (f) 3D MRCP images. On the precontrast CT image (a), in the common bile duct, two high-density nodules (arrow) can be seen, which can be identified as common bile duct stones. On the contrast-enhanced CT image (b), the opacification of common bile duct stones (arrow) becomes faint due to both the effect of contrast enhancement on the surrounding organs and the different setting of window width and window level. On the T1-weighted MR image (c), a clear area of hyperintensity is evident (arrow). Because stones appear as signal void on the T2-weighted images, the stones (arrow) in image (d) are clearly contrasted within the bile duct, which is filled with hyperintense bile. On the coronal T2-weighted MR image (e), two common bile duct stones can be clearly identified (arrows). On the MRCP image (f), the stones appear as signal voids (arrows). In this patient, the left hepatic duct first branches to the right of the right hepatic duct, then branches ventrally to the right hepatic duct (anatomical variation). A stone is also present in the left hepatic duct (arrowhead), and the distal bile duct in the lateral segment is dilated. Note: the asterisk (\*) indicates a hepatic cyst

Q8. Are dynamic CT and dynamic MRI imaging methods useful in the diagnosis of acute cholangitis? [Future research question]

Research suggests that dynamic CT and dynamic MRI imaging might be useful test methods in the diagnosis of acute cholangitis. (Level D)

Although methods for the direct imaging of AC have yet to be established, research suggests that transient hyperattenuation differences (THAD) in the hepatic parenchyma on early-phase of dynamic CT as well as transient heterogeneous enhancement in the hepatic parenchyma on early-phase of dynamic MRI may provide a specific imaging finding for AC [35]. Other recent studies have also suggested that THAD may be useful for severity grading [30, 36, 37].

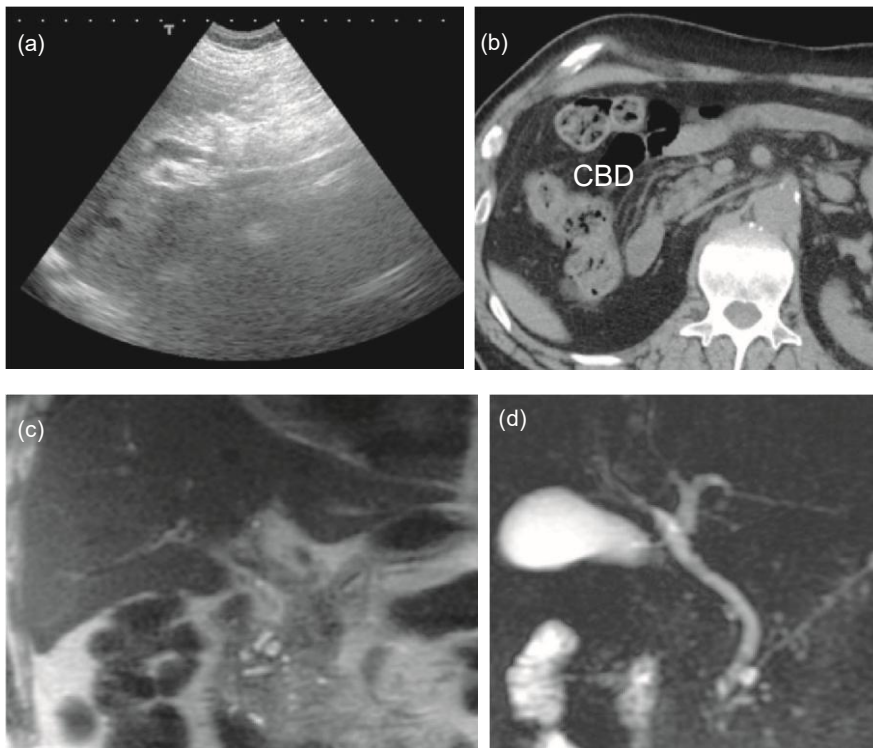


Fig. 4 Example of non-incarcerated common bile duct stones. (a) Abdominal ultrasound, (b) plain CT, (c) coronal T2-weighted MRI, and (d) MRCP images. On the B-mode ultrasound image (a), a hyperechoic structure with faint acoustic shadow can be seen (arrow) in the common bile duct. On the plain CT image (b), any bile duct stones in the common bile duct (arrow) cannot be identified and there is no evidence of bile duct dilatation (not shown). On the T2-weighted MRI image (c), two hypointense nodules are apparent (arrows) in the common bile duct. The same common bile duct stones can also be identified (arrows) on the MRCP image (d). No dilation of the upstream bile duct is observed

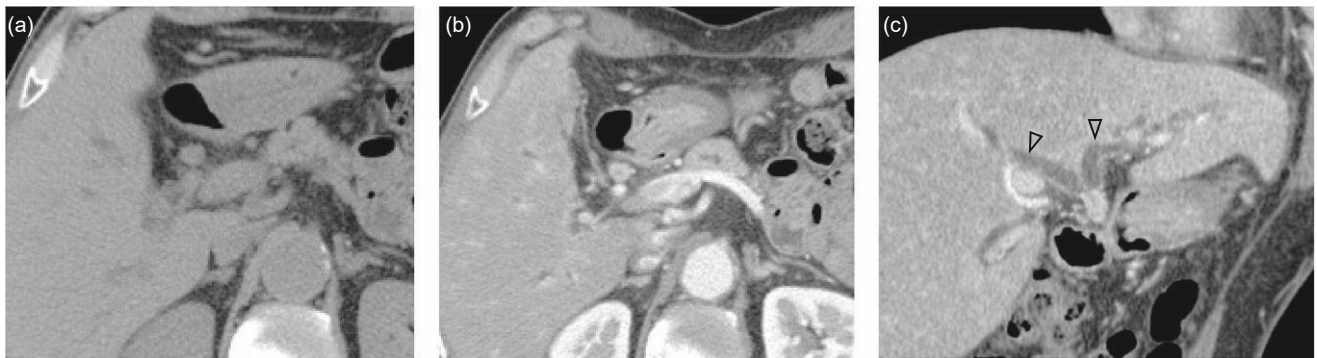


Fig. 5 Example of extrahepatic bile duct cancer. (a) Precontrast CT, (b) early-phase of dynamic contrast-enhanced CT, and (c) its coronal reconstruction images. On the precontrast CT image (a), circumferential thickening of the wall of the upper bile duct is evident (arrow). On the contrast-enhanced CT image (b), the circumferential thickening of the wall of the upper bile duct is clearly contrasted (arrow). On the coronal contrast-enhanced CT image (c), thickening of the wall of the upper bile duct is clearly apparent (arrows). Upstream biliary dilatation is clearly visible (arrowheads). Heterogeneous contrast enhancement of the hepatic parenchyma is also evident (b, c), suggesting that acute cholangitis has developed as a secondary condition

Transient hyperattenuation differences may be caused by increased arterial blood flow accompanying biliary inflammation [29]. THAD is hardly seen in healthy individuals (1.78 to 5% of cases), but is seen in 67.9 to 85% of patients with AC [35, 38] (Figs 8, 9, and Videos S1, S2). A study has also shown that dynamic MRI shows the

transient periductal signal difference, which is nearly equal to THAD on early-phase of dynamic CT, in a high percentage of patients with AC [34]. Various studies have suggested that THAD may be useful in the diagnosis of AC and also as a predictive factor for severity: one study reported good diagnostic capabilities

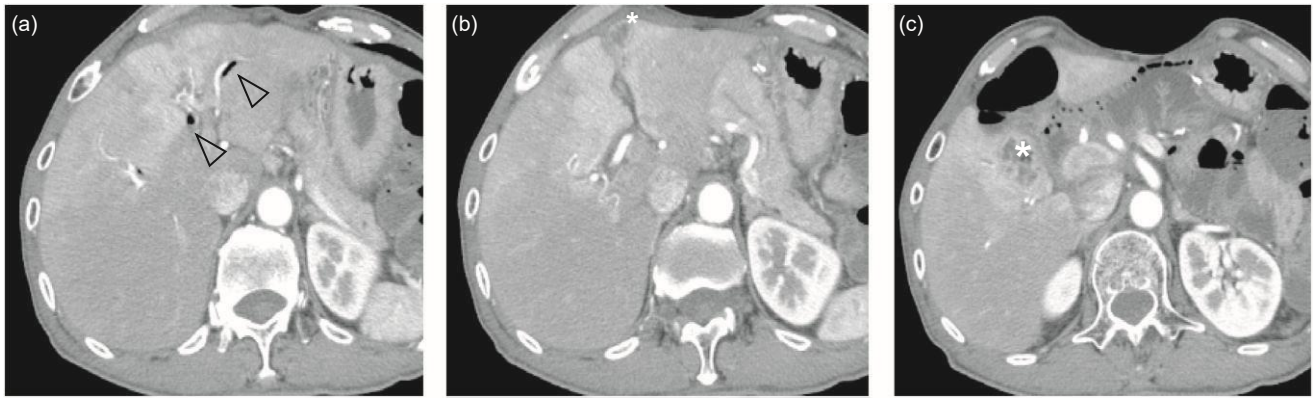


Fig. 6 Example of acute cholangitis and hepatic abscess in a patient with a surgical history of duodenal cancer and bile duct reconstruction (choledochojejunostomy). Early-phase of dynamic CT image series (a), (b), (c) (caudal to cranial). Irregular early enhancement of the hepatic parenchyma is apparent (arrows). Pneumobilia is evident in the bile duct (arrowheads). A multilocular cyst is in S3 and S5 (asterisks in (b) and (c)), the walls of which are enhanced. After antibacterial treatment, this lesion disappeared, suggesting a hepatic abscess

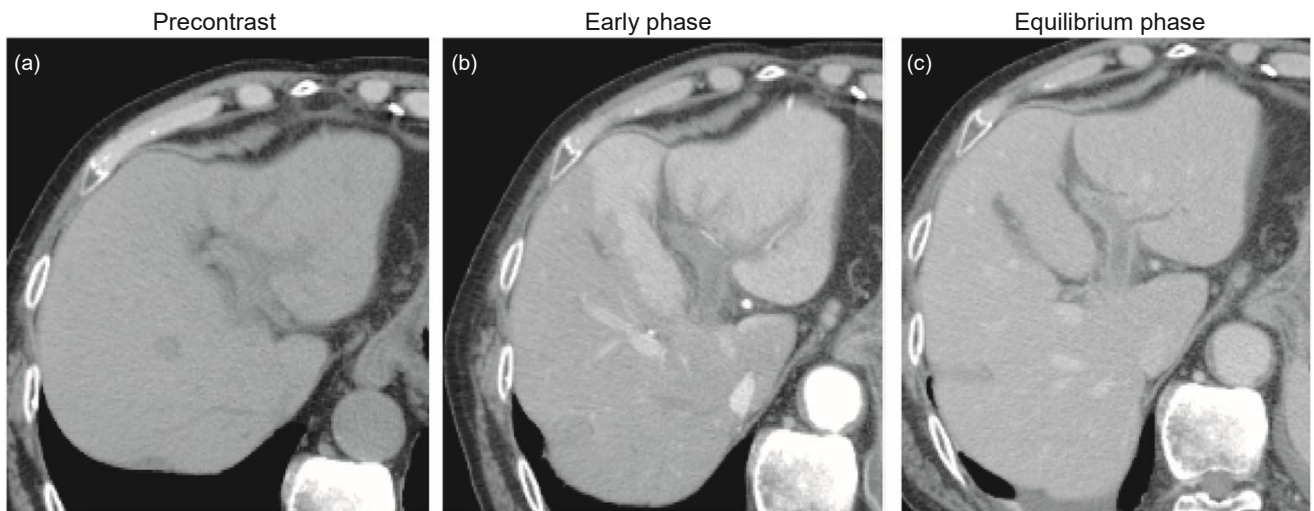


Fig. 7 Example of acute cholangitis with portal vein thrombosis: dynamic contrast-enhanced CT. On the precontrast CT image (a), a faint hyperdensity (arrow) is seen in the umbilical portion of the portal vein. The left branch of the portal vein is not enhanced (arrows in b, c), suggesting portal vein thrombosis. In the early phase (b), segmental early enhancement is present in the left lobe (inside of the broken lines), but in the equilibrium phase this is unclear, which is a sign of compensatory increased arterial blood flow associated with reduced portal vein blood flow

for AC using a scoring method based on the degree of THAD spread, bile duct diameter, and presence of occlusive lesions [36]; another study found correlation between the degree of THAD spread and C-reactive protein, leukocyte count, and clinical symptoms like abdominal pain and fever [39]; another study demonstrated the utility of THAD in differentiating between acute suppurative cholangitis and acute non-suppurative cholangitis [30]; and yet another study assessed THAD in 93 AC patients divided into two groups according to whether overall biliary dilatation was observed – the results showed that the extent of THADs was significantly smaller in the group without biliary dilatation than in the group with biliary dilatation [37]. However, another

imaging analysis study on 123 patients before biliary drainage was performed, divided into two groups according to whether the patients had AC, reported no relationship between the degree of THAD and degree of severity [40], which was inconsistent with the other reports suggesting usefulness in severity grading. THAD is observed in a wide range of diseases, including acute pancreatitis, pyelonephritis, and pneumonia, so this method may not be expected to be highly specific. As such, although research suggests that THAD may be useful in the diagnosis of AC, given the current paucity of evidence, further clinical studies are needed to determine its usefulness (in the diagnosis and severity assessment of AC).

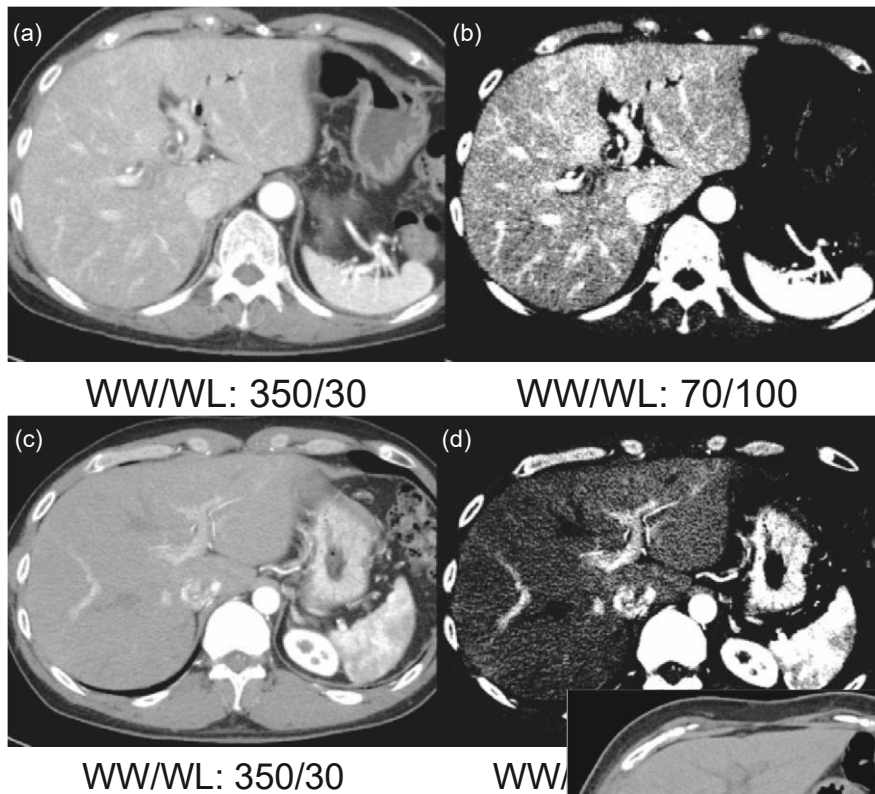


Fig. 8 Examples of a patient with acute cholangitis (a, b) and healthy individual (c, d). CT images under two display conditions. (a) Under the typical conditions, diffuse heterogeneous early enhancement of the liver is clearly apparent. The diffuse heterogeneous early enhancement of the liver in this patient is weaker in the healthy individual (c). Given that no abnormal liver enhancement can be identified in image (d), even at the typical window level, WL window level, WW window width, WL window level, WW window width

Severity grading criteria for acute cholangitis

Q9. Are the TG13 severity grading criteria for acute cholangitis useful for clinical practice and appropriate as the TG18 criteria? [Foreground question]

The TG13 severity grading criteria are recommended to be used as the TG18 criteria because patients whose prognosis can potentially be improved by early biliary drainage can be identified by using these criteria. (Recommendation 1, level D)

The entire literature on TG13 severity grading criteria consisted of four case series studies [17, 18, 41, 42], again illustrating the paucity of research in this area.

The TG13 severity grading criteria for AC are important for predicting prognosis and determining a treatment strategy, especially identifying patients that require early biliary drainage.

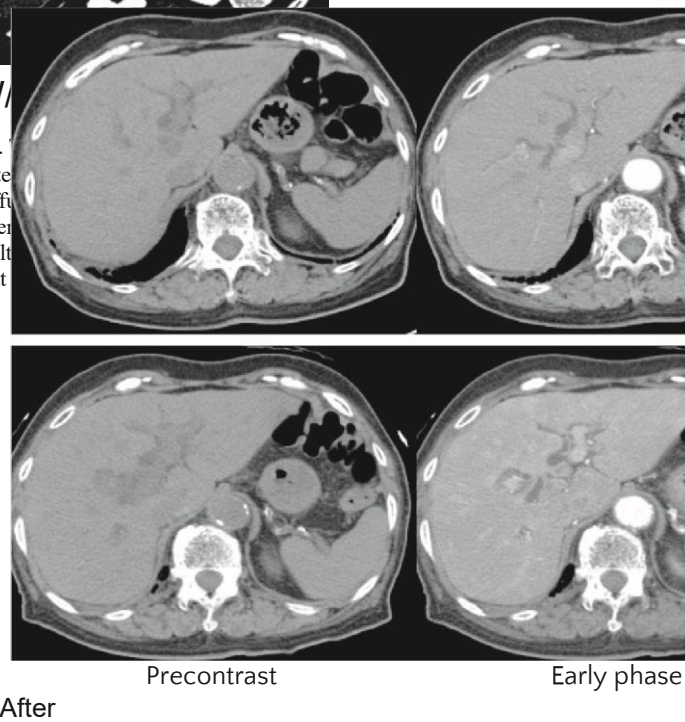


Fig. 9 Images change before and after the onset of acute cholangitis. Before (top row) and after (bottom row) the onset of acute cholangitis, biliary dilatation can be identified on both precontrast and contrast-enhanced CT. In early phase (center of the top row), liver enhancement of the liver is more obvious after the onset of acute cholangitis (center of the top row). This enhancement disappeared during the late phase (THAD) (Video)

Three of the case series studies mentioned above discuss prognostic factors in the TG13 severity grading criteria. In a large, multicenter case series study on patients with AC conducted in Japan and Taiwan, application of the TG13 severity grading criteria to the case series yielded 1,521 patients with Grade III (25.1%), 2,019 patients with Grade II (33.3%), and 2,523 patients with Grade I (41.6%). In patients with a higher severity grading, 30-day mortality was significantly higher. However, no correlation between severity grading and 30-day mortality was observed in patients with AC caused by malignant tumors [17]. One of the problems with the TG13 severity grading criteria is that the Grade III prognostic factors are all assigned the same weight, which has resulted in univariate analysis identifying “disturbance of consciousness” as the most important predictor of risk [41]. In the multicenter study in Japan and Taiwan, the Grade III prognostic factors (other than hepatic dysfunction) shown by multivariate analysis to be significant all had roughly equal weights. For Grade II, white blood cell count abnormalities and hypoalbuminemia have been shown to be significant prognostic factors [17]. In terms of predictors of poor outcomes, whereas univariate analysis has identified renal failure, hepatic dysfunction, intrahepatic

biliary stenosis, AC caused by malignant disease, and hypoalbuminemia as significant predictors of 30-day mortality, multivariate analysis has identified only intrahepatic biliary stenosis and hypoalbuminemia [18]. As evidenced by the above, different studies have produced different results related to the weighting of each factor, with one report even identifying hepatic dysfunction as a significant prognostic factor; these varied results have led to inconsistent conclusions.

Only two of the case series studies evaluated the TG13 severity grading criteria as an indicator for biliary drainage [17, 42]. In the multicenter case series study performed in Japan and Taiwan, patients were divided into two groups – those treated with early or urgent biliary drainage and those that were not; the 30-day mortality of the two groups were compared. No difference was observed between groups for patients with Grade I or Grade III AC; however, 30-day mortality was significantly lower in patients with Grade II AC who were treated with early or urgent biliary drainage (Table 3) [17]. This suggests that the TG13 severity grading criteria for AC can be used to identify Grade II patients whose prognoses may be improved through biliary

Table 3 Thirty-day mortality rate relevant to the timing of biliary drainage and severity grading by TG13 [17]

Severity grade	30-day mortality according to the timing or absence of biliary drainage					
	Urgent biliary drainage			Urgent or early biliary drainage		
	Within 24 h (n = 2,709)	After 24 h or absence (n = 3,354)	P-value	Within 48 h (n = 3,730)	After 48 h or absence (n = 2,333)	P-value
Grade III (n = 1,521)	5.4% (42/781)	4.9% (36/740)	0.727	4.9% (50/1,017)	5.6% (28/504)	0.622
Grade II (n = 2,019)	1.7% (16/939)	3.4% (37/1,080)	<0.05	2.0% (25/1,272)	3.7% (28/747)	<0.05
Grade I (n = 2,523)	1.3% (13/989)	1.2% (18/1,534)	0.853	1.1% (16/1,441)	1.4% (15/1,082)	0.586
Total (n = 6,063)	2.6% (71/2,709)	2.7% (91/3,354)	0.873	2.4% (91/3,730)	3.0% (71/2,333)	0.164

Urgent performed on the admission day (within 24 h), early performed on the day following admission (24–48 h)

Cited from Kiriya et al. [17]

Table 4 TG18/TG13 severity assessment criteria for acute cholangitis [4]

Grade III (severe) acute cholangitis

“Grade III” acute cholangitis is defined as acute cholangitis that is associated with the onset of dysfunction at least in any one of the following organs/systems:

1. Cardiovascular dysfunction: hypotension requiring dopamine  $\geq 5$  lg/kg per min, or any dose of norepinephrine
2. Neurological dysfunction: disturbance of consciousness
3. Respiratory dysfunction: PaO<sub>2</sub>/FiO<sub>2</sub> ratio <300
4. Renal dysfunction: oliguria, serum creatinine >2.0 mg/dl
5. Hepatic dysfunction: PT-INR >1.5
6. Hematological dysfunction: platelet count <100,000/mm<sup>3</sup>

Grade II (moderate) acute cholangitis

“Grade II” acute cholangitis is associated with any two of the following conditions:

1. Abnormal WBC count ( $>12,000/\text{mm}^3$ ,  $<4,000/\text{mm}^3$ )
2. High fever ( $\geq 39^\circ\text{C}$ )
3. Age ( $\geq 75$  years old)
4. Hyperbilirubinemia (total bilirubin  $\geq 5$  mg/dl)
5. Hypoalbuminemia ( $< \text{STD}^a 90.7$ ) Grade I (mild) acute cholangitis

"Grade I" acute cholangitis does not meet the criteria of "Grade III (severe)" or "Grade II (moderate)" acute cholangitis at initial diagnosis.

Early diagnosis, early biliary drainage and/or treatment for etiology, and antimicrobial administration are fundamental treatment for acute cholangitis classified not only "Grade III (severe)" and "Grade II (moderate)" but also "Grade I (mild)".

Therefore, it is recommended that patients with acute cholangitis who do not respond to the initial medical treatment (general supportive care and antimicrobial therapy) undergo early biliary drainage or treatment for etiology (see flowchart).

Cited from Kiriya et al. [4]

<sup>a</sup> STD: lower limit of normal value

drainage. For Grade III patients, no difference in prognosis was seen even when patients were treated with early or urgent biliary drainage. This study defined urgent drainage as being performed within 24 h of admission, whereas the two other studies defined urgent drainage as being performed within 12 h [18, 42]. Given the possibility that the prognosis for Grade III patients may be improved if biliary drainage is performed at an even earlier stage, further research is warranted. It has also been suggested that some of the patients requiring early or urgent drainage might have been misclassified as Grade I patients [42]. However, the study consisted of only a small case series, and it is not clear what types of patients were misclassified in this way.

When establishing prognoses using the TG13 severity grading criteria, there are problems with AC caused by malignant disease, but it can be useful to look at the correlation between severity grading and mortality rates. However, different studies have produced varying results in terms of the weighting of each prognostic factor, including the predictive value of hepatic dysfunction; as such, various issues still need to be resolved. The TG13 criteria are also useful as an indicator for biliary drainage by enabling the identification of patients requiring early biliary drainage as Grade II. Because Grade II patients have not yet progressed to organ dysfunction but are at risk of doing so, the severity grading criteria for Grade II cholangitis requiring early biliary drainage were the most important issue discussed when revising and repackaging the TG07 guidelines as the TG13 guidelines. For diagnosis and treatment of AC patients in the clinical setting, an indicator for biliary drainage is more meaningful than a prognostic prediction. The TG13 severity grading criteria allow assessment based on clinical signs and symptoms and routine blood tests that can be performed and provide results quickly, are minimally invasive for the patient, and are inexpensive. As such, we recommend that the TG13 severity grading criteria for AC

be adopted as TG18 severity grading criteria and used as standard practice in the clinical setting. Table 4 shows the TG18/TG13 severity grading criteria for AC. At the Updating Tokyo Guidelines Public Hearing, a majority of attendees (93.7%) agreed that the TG13 severity grading criteria should be adopted as the TG18/TG13 severity grading criteria (Fig. 10).

Q10. Is procalcitonin useful for diagnosis and severity assessment for acute cholangitis? [Future research question]

Procalcitonin is suggested as a useful parameter for the severity assessment of acute cholangitis. (Level D)

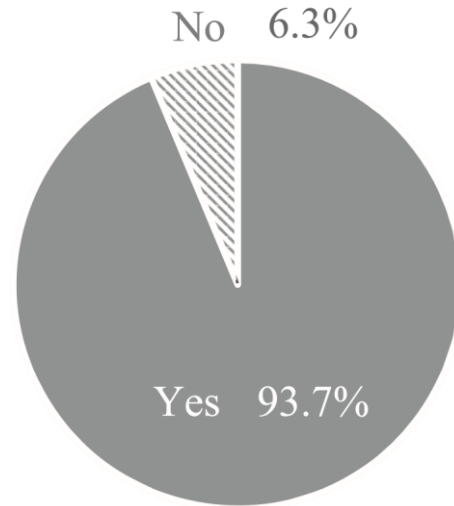


Fig. 10 Response to the question: "Do you agree with the suggestion that TG13 severity grading criteria for acute cholangitis would be adopted as the TG13/TG18 criteria without revising setting?"

Acute cholangitis occurs when biliary stenosis results in bile backing up and becoming infected. This blockage elevates pressure within the biliary system and results in the infected bile being flushed into systemic circulation,

inducing a systemic inflammatory response. The patient can develop septicemia if this situation continues. Severe AC can lead to organ failure due to septicemia; a recent report has suggested that measurement of serum procalcitonin, a serum marker for septicemia, can provide a simpler and faster method to assess the severity of AC.

Three case series studies have investigated the relationship between serum procalcitonin levels and the severity of AC. One study reported significantly higher levels of serum procalcitonin in patients assessed as having severe AC based on the TG07 severity grading criteria [43]. Another study reported significantly higher levels in patients assessed as having severe AC based on the TG13 severity grading criteria compared with patients assessed as mild AC [44]. Finally, the third study reported that serum procalcitonin levels increased with severity based on the TG13 guidelines [45]. These results suggest that serum procalcitonin levels are useful when assessing the severity of AC. However, as this research only includes small-scale case series studies in single institutions and the current body of evidence remains small, further clinical research is needed to evaluate the usefulness of this method.

## References

- Lipsett PA, Pitt HA. Acute cholangitis. *Surg Clin North Am*. 1990;70:1297–312.
- Wada K, Takada T, Kawarada Y, Nimura Y, Miura F, Yoshida M, et al. Diagnostic criteria and severity assessment of acute cholangitis: Tokyo Guidelines. *J Hepatobiliary Pancreat Surg*. 2007;14:52–8.
- Yokoe M, Takada T, Mayumi T, Yoshida M, Hasegawa H, Norimizu S, et al. Accuracy of the Tokyo Guidelines for the diagnosis of acute cholangitis and cholecystitis taking into consideration the clinical practice pattern in Japan. *J Hepatobiliary Pancreat Sci*. 2011;18:250–7.
- Kiriyama S, Takada T, Strasberg SM, Solomkin JS, Mayumi T, Pitt HA, et al. New diagnostic criteria and severity assessment of acute cholangitis in revised Tokyo Guidelines. *J Hepatobiliary Pancreat Sci*. 2012;19:548–56.
- Kiriyama S, Takada T, Strasberg SM, Solomkin JS, Mayumi T, Pitt HA, et al. TG13 guidelines for diagnosis and severity grading of acute cholangitis (with videos). *J Hepatobiliary Pancreat Sci*. 2013;20:24–34.
- Tsuyuguchi T, Sugiyama H, Sakai Y, Nishikawa T, Yokosuka O, Mayumi T, et al. Prognostic factors of acute cholangitis in cases managed using the Tokyo Guidelines. *J Hepatobiliary Pancreat Sci*. 2012;19:557–65.
- Takada T, Strasberg SM, Solomkin JS, Gomi H, Yoshida M, Mayumi T, et al. TG13: Updated Tokyo Guidelines for the management of acute cholangitis and cholecystitis. *J Hepatobiliary Pancreat Sci*. 2013;20:1–7.
- Charcot M. De la fièvre hépatique symptomatique. Comparaison avec la fièvre uroseptique. Leçons sur les maladies du foie des voies biliaires et des reins. Paris: Bourneville et Sevestre; 1877. p. 176–85
- Csendes A, Diaz JC, Burdiles P, Maluenda F, Morales E. Risk factors and classification of acute suppurative cholangitis. *Br J Surg*. 1992;79:655–8.
- Welch JP, Donaldson GA. The urgency of diagnosis and surgical treatment of acute suppurative cholangitis. *Am J Surg*. 1976;131:527–32.
- Thompson JE Jr, Tompkins RK, Longmire WP Jr. Factors in management of acute cholangitis. *Ann Surg*. 1982;195:137–45.
- Gigot JF, Leese T, Dereme T, Coutinho J, Castaing D, Bismuth H. Acute cholangitis. Multivariate analysis of risk factors. *Ann Surg*. 1989;209:435–8.
- Boey JH, Way LW. Acute cholangitis. *Ann Surg*. 1980;191: 264–70.
- O'Connor MJ, Schwartz ML, McQuarrie DG, Sumer HW. Acute bacterial cholangitis: an analysis of clinical manifestation. *Arch Surg*. 1982;117:437–41.
- Lai EC, Tam PC, Paterson IA, Ng MM, Fan ST, Choi TK, et al. Emergency surgery for severe acute cholangitis. The high-risk patients. *Ann Surg*. 1990;211:55–9.
- Haupt AP, Carey LC, Evans WE, Ellison EH. Acute suppurative cholangitis. Experience with 15 consecutive cases. *Arch Surg*. 1967;94:460–8.
- Kiriyama S, Takada T, Hwang T-L, Akazawa H, Miura F, Gomi H, et al. Clinical application and verification of the TG13 diagnostic and severity grading criteria for acute cholangitis: an international multicenter observational study. *J Hepatobiliary Pancreat Sci*. 2017;24:329–37.
- Sun G, Han L, Yang Y, Linghu E, Li W, Cai F, et al. Comparison of two editions of Tokyo guidelines for the management of acute cholangitis. *J Hepatobiliary Pancreat Sci*. 2014;21:113–9.
- Badea R, Zaro R, Tantau M, Chiorean L. Ultrasonography of the biliary tract - up to date. The importance of correlation between imaging methods and patients' signs and symptoms. *Med Ultrason*. 2015;17:383–91.
- Tamm EP, Balachandran A, Bhosale P, Szklaruk J. Update on 3D and multiplanar MDCT in the assessment of biliary and pancreatic pathology. *Abdom Imaging*. 2009;34:64–74.
- Arrive L, Hodoul M, Arbache A, Slavikova-Boucher L, Menu Y, El Mouhadi S. Magnetic resonance cholangiography: current and future perspectives. *Clin Res Hepatol Gastroenterol*. 2015;39:659–64.
- Williams EJ, Green J, Beckingham I, Parks R, Martin D, Lombard M, et al. Guidelines on the management of common bile duct stones (CBDS). *Gut*. 2008;57:1004–21.
- Abboud PAC, Malet PF, Berlin JA, Staroscik R, Cabana MD, Clarke JR, et al. Predictors of common bile duct stones prior to cholecystectomy: A meta-analysis. *Gastrointest Endosc*. 1996;44:450–7.
- Karki S, Joshi K, Regmi S, Gurung R, Malla B. Role of ultrasound as compared with ERCP in patient with obstructive jaundice. *Kathmandu Univ Med J*. 2015;11:237–40.
- Rickes S, Treiber G, Mecklinger K, Peitz U, Csepregi A, Kahl S, et al. Impact of the operator's experience on value of high-resolution transabdominal ultrasound in the diagnosis of choledocholithiasis: a prospective comparison using endoscopic retrograde cholangiography as the gold standard. *Scand J Gastroenterol*. 2006;41:838–43.

26. Lee JK, Kim TK, Byun JH, Kim AY, Ha HK, Kim PN, et al. Diagnosis of intrahepatic and common duct stones: combined unenhanced and contrast-enhanced helical CT in 1090 patients. *Abdom Imaging*. 2006;31:425–32.
27. Patel NB, Oto A, Thomas S. Multidetector CT of emergent biliary pathologic conditions. *Radiographics*. 2013;33:1867–88.
28. Yoon K-H, Ha HK, Lee JS, Suh JH, Kim MH, Kim PN, et al. Inflammatory pseudotumor of the liver in patients with recurrent pyogenic cholangitis: CT-histopathologic correlation 1. *Radiology*. 1999;211:373–9.
29. Gabata T, Kadoya M, Matsui O, Kobayashi T, Kawamori Y, Sanada J, et al. Dynamic CT of hepatic abscesses: significance of transient segmental enhancement. *AJR Am J Roentgenol*. 2001;176:675–9.
30. Lee NK, Kim S, Lee JW, Kim CW, Kim GH, Kang DH, et al. Discrimination of suppurative cholangitis from nonsuppurative cholangitis with computed tomography (CT). *Eur J Radiol*. 2009;69:528–35.
31. Watanabe Y, Nagayama M, Okumura A, Amoh Y, Katsube T, Suga T, et al. MR imaging of acute biliary disorders. *Radiographics*. 2007;27:477–95.
32. Gabata T, Kadoya M, Matsui O, Kobayashi T, Sanada J, Mori A. Intrahepatic biliary calculi: correlation of unusual MR findings with pathologic findings. *Abdom Imaging*. 2000;25:266–8.
33. Singh A, Mann HS, Thukral CL, Singh NR. Diagnostic accuracy of MRCP as compared to ultrasound/CT in patients with obstructive jaundice. *J Clin Diagn Res*. 2014;8:103–7.
34. Eun HW, Kim JH, Hong SS, Kim YJ. Assessment of acute cholangitis by MR imaging. *Eur J Radiol*. 2012;81:2476–80.
35. Arai K, Kawai K, Kohda W, Tatsu H, Matsui O, Nakahama T. Dynamic CT of acute cholangitis: early inhomogeneous enhancement of the liver. *AJR Am J Roentgenol*. 2003;181:115–8.
36. Kim SW, Shin HC, Kim HC, Hong MJ, Kim IY. Diagnostic performance of multidetector CT for acute cholangitis: evaluation of a CT scoring method. *Br J Radiol*. 2012;85:770–7.
37. Hong MJ, Kim SW, Kim HC, Yang DM. Comparison of the clinical characteristics and imaging findings of acute cholangitis with and without biliary dilatation. *Br J Radiol*. 2012;85:e1219–25.
38. Pradella S, Centi N, La Villa G, Mazza E, Colagrande S. Transient hepatic attenuation difference (THAD) in biliary duct disease. *Abdom Imaging*. 2009;34:626–33.
39. Kim SW, Shin HC, Kim IY. Transient arterial enhancement of the hepatic parenchyma in patients with acute cholangitis. *J Comput Assist Tomogr*. 2009;33:398–404.
40. Sugishita T, Higuchi R, Morita S, Ota T, Yamamoto M. Diagnostic accuracy of transient hepatic attenuation differences on computed tomography scans for acute cholangitis in patients with malignant disease. *J Hepatobiliary Pancreat Sci*. 2014;21: 669–75.
41. Schneider J, Hapfelmeier A, Th€ores S, Obermeier A, Schulz C, Pff€orringer D, et al. Mortality Risk for Acute Cholangitis (MAC): a risk prediction model for in-hospital mortality in patients with acute cholangitis. *BMC Gastroenterol*. 2016;16:15.
42. Nishino T, Hamano T, Mitsunaga Y, Shirato I, Shirato M, Tagata T, et al. Clinical evaluation of the Tokyo Guidelines 2013 for severity assessment of acute cholangitis. *J Hepatobiliary Pancreat Sci*. 2014;21:841–9.
43. Hamano K, Noguchi O, Matsumoto Y, Watabe T, Numata M, Yosioka A, et al. Usefulness of procalcitonin for severity assessment in patients with acute cholangitis. *Clin Lab*. 2013;59: 177–83.
44. Shinya S, Sasaki T, Yamashita Y, Kato D, Yamashita K, Nakashima R, et al. Procalcitonin as a useful biomarker for determining the need to perform emergency biliary drainage in cases of acute cholangitis. *J Hepatobiliary Pancreat Sci*. 2014;21:777–85.
45. Umefune G, Kogure H, Hamada T, Isayama H, Ishigaki K, Takagi K, et al. Procalcitonin is a useful biomarker to predict severe acute cholangitis: a single-center prospective study. *J Gastroenterol*. 2016;52:734–45.